



PATIENT

Henry Pinheiro

PRESENTING CLINICAL SIGNS

History: Recheck holter after starting atenolol.
 Pertinent previous holter findings (MML 8/2022): 768 single VPCs; no meds indicated, rec echo.
 Echo findings (AK11/2022): Valvular PS; moderate, type A. ECG showed VPCs.
 Current medications: Atenolol 50mg BID

SPECIES

Canine

HOLTER MONITOR FINDINGS AND RHYTHM ASSESSMENT

BREED

Pitbull

Time analyzed	24:11h
Mean heart rate	52bpm
Maximum heart rate	183bpm
Minimum heart rate	27bpm
VPCs	8 singles
APCs	0

SEX

Male Neutered

Interpretation: Underlying normal sinus rhythm with appropriate rate variation. Resting heart rate is low secondary to atenolol therapy. Max heart rate is sinus in origin and occurs with activity. Rare VPCs persist. The reported couplet is benign and consistent with an escape foci; instantaneous HR 100bpm.

AGE

6 years

WEIGHT

81 lbs

Rhythm diagnosis: Sinus rhythm with rare VPCs; heart rate controlled with atenolol.

INTERPRETED BY

Maggie Machen Lamy,
 DVM, DACVIM
 (Cardiology)

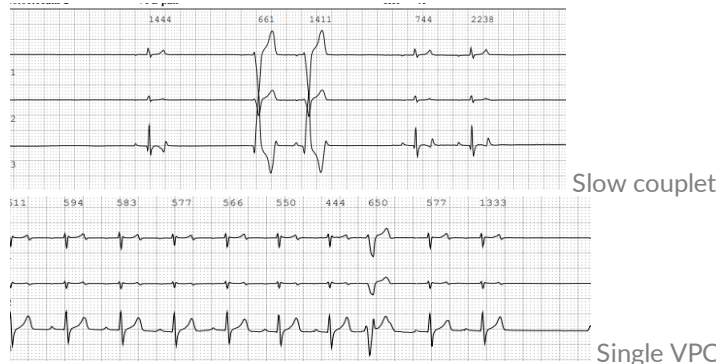
RECOMMENDATIONS

Compared to the prior holter, there is significant improvement in frequency of ectopy. The numeric count has dropped from 768 to 8, with a reasonable resting heart rate. The sinus rate is able to stimulate with activity briefly; however, the resting rate is within the target zone. As long as the patient is not symptomatic, continuing at the current dose is suggested.

Recheck ECG in 6 months, sooner if any syncope is noted. Recheck echo as dictated by the prior report.

IMAGING PERFORMED BY

IMAGES



HOSPITAL NAME

Mass Veterinary Services

REFERRING VET

Dr. Chameroy

INVOICE

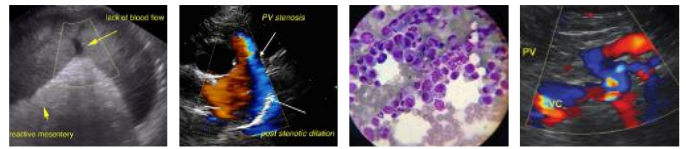
28686a

The information and recommendations provided are based on the images presented by the referring veterinarian. No evaluation can be communicated regarding pathology that was not visible in the image/video clips provided.

DATE

1/30/23

Thank you for this referral. If the clinical or image interpretation does not parallel your findings or if I can be of any further assistance please contact me.



PATIENT

Henry Pinheiro

Maggie Machen Lamy, DVM

Diplomate of the American College of Veterinary Internal Medicine (Cardiology)

info@sonopath.com

SPECIES

Canine

BREED

Pitbull

SEX

Male Neutered

AGE

6 years

WEIGHT

81 lbs

INTERPRETED BY

Maggie Machen Lamy,
DVM, DACVIM
(Cardiology)

**IMAGING
PERFORMED BY**

HOSPITAL NAME

Mass Veterinary
Services

REFERRING VET

Dr. Chameroy

INVOICE

28686a

DATE

1/30/23